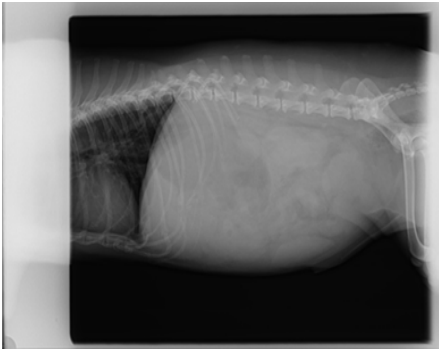


# Septic Peritonitis

## CASE STUDY – HBOT & VETERINARY MEDICINE

**GiGi**



**Pre Radiograph on  
6/23**

- Culture of the abdominal fluid yielded a bacterial growth (Klebsiella)
- Treated with enrofloxacin, ticarcillin / clavulanic acid, and Hyperbaric Oxygen Therapy.

Hyperbaric Oxygen Therapy Dates:

6/24 – 1 treatment

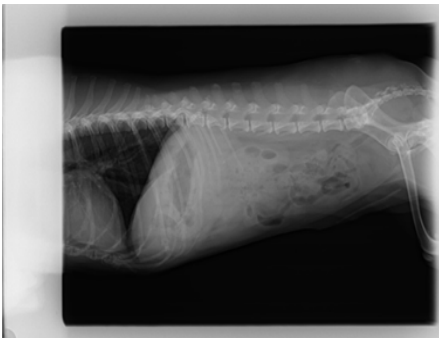6/25 – 2 treatments

6/26 – 2 treatments

6/27 – 2 treatments

6/28 – 2 treatments

6/29 – 2 treatments



**Post Radiograph on  
6/29**

This canine developed Peritonitis. E. coli was cultured from the fluid. No evidence for intestinal perforation or obstruction was found. IV fluids, antibiotics, and HBOT were given and the peritonitis resolved.