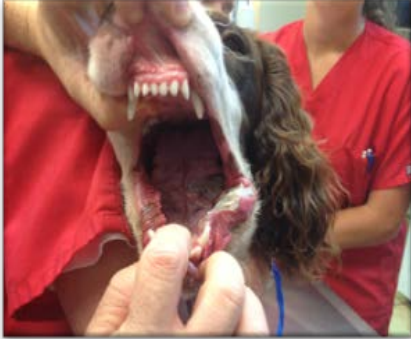

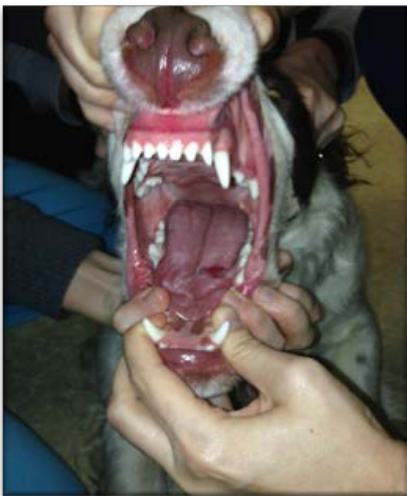
Electric Cord Bite with Thermal Burns in a Canine

CASE STUDY – HBOT & VETERINARY MEDICINE

Diesel



**Hyperbaric
Oxygen Therapy
11/18**



**17 Days after
Hyperbaric
Oxygen
Treatments**

Hyperbaric Oxygen Therapy Dates:

11/14 – 1 treatment
11/15 – 2 treatments
11/16 – 2 treatments
11/17 – 2 treatments
11/18 – 1 treatment

A young canine was found salivating and pawing at his mouth next to a “chewed” electric cord plugged into a lamp. A large linear burn lesion was discovered on his tongue. Adjunctive HBOT was given along with other methods of pain management and antibiotic therapy.

© RKLyman, LLC. All Rights Reserved.

